

Medical Technology CT


Computed Tomography Certification Exam

For More Information – Visit link below:

<https://www.examsempire.com/>

Product Version

- 1. Up to Date products, reliable and verified.**
- 2. Questions and Answers in PDF Format.**



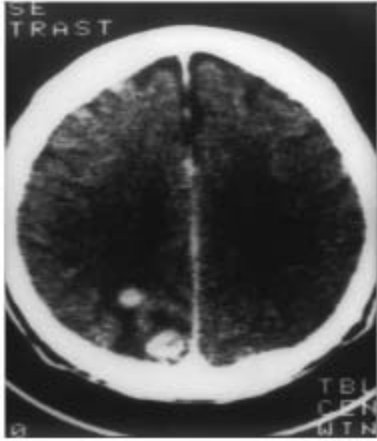
<https://examsempire.com/>

Visit us at: <https://www.examsempire.com/ct>

Latest Version: 6.1

Question: 1

What imaging plane is displayed in the below brain CT?

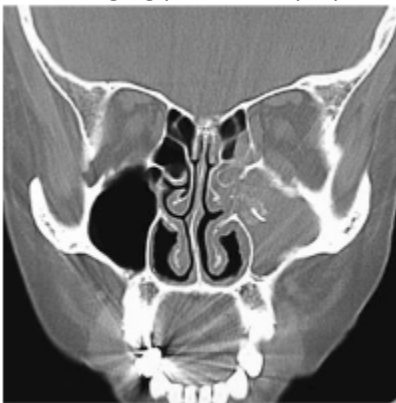


- A. Sagittal
- B. Axial
- C. Coronal
- D. Oblique

Answer: B

Question: 2

What imaging plane is displayed on the below sinus CT image?



- A. Sagittal
- B. Axial
- C. Coronal

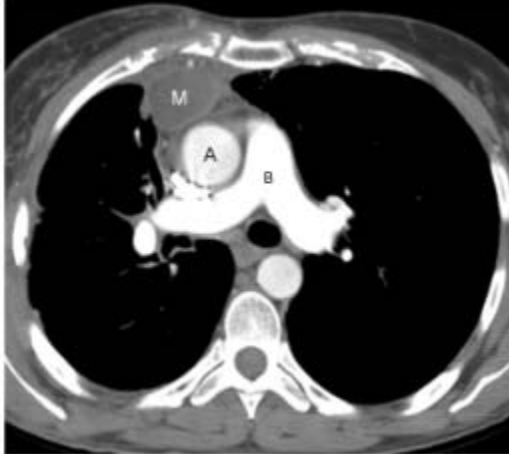
D. Oblique

Answer: C

Explanation:

Question: 3

What anatomy is represented on letter B?



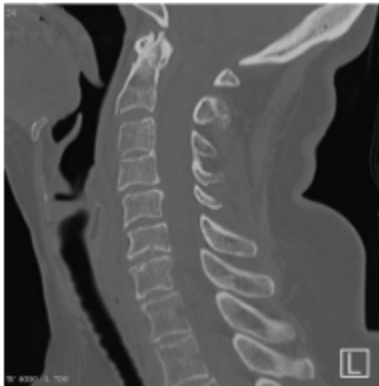- A. Aorta
- B. Main pulmonary artery
- C. IVC
- D. Pulmonary vein

Answer: B

Explanation:

Question: 4

What imaging plane is displayed on the below cervical spine CT image?



- A. Sagittal
- B. Axial
- C. Coronal
- D. Oblique

Answer: A

Question: 5

What are the two phases of the non-equilibrium phase utilized for bi-phasic studies of the pancreas and liver?

- A. Hepatic arterial and portal venous
- B. Bolus and equilibrium
- C. Hepatic arterial and bolus
- D. Portal venous and equilibrium

Answer: A

Explanation:

There are 3 phases of contrast enhancement: bolus, non-equilibrium, and equilibrium phases. The first phase of enhancement is the bolus phase. This is an optimal phase for CTAs. There is a significant density difference between the abdominal aorta and IVC. The second phase is the non-equilibrium phase. During this phase, the bolus disperses into the capillaries and then into the veins. The two phases of enhancement within this phase are the hepatic arterial (typically about 25 second's post-contrast injection) and portal venous. The non-equilibrium phase provides the best differentiation of structures in soft tissue, like the liver and pancreas. The third phase is equilibrium. During this phase, the concentration of contrast in the veins and arteries are similar and soft tissue differentiation becomes diminished.

Question: 6

What is the lowest acceptable volume of oral contrast agent to still provide an optimal bowel opacification?

- A. 200 mL
- B. 300 mL
- C. 600 mL
- D. 100 mL

Answer: C

Explanation:

Overall patient health and general compliance will affect how much volume will be consumed. Some patients are vomiting and too nauseous to drink the required volume of oral prep. Other patients simply refuse to drink the oral prep. The greater the volume of oral contrast consumed, the better the bowel opacification. At least 600 mL of oral contrast is desired for the best bowel opacification.

Question: 7

What is the best reason for utilizing oral contrast to opacify the GI tract?

- A. Distention of the GI tract
- B. Differentiates fluid filled bowel from a mass or abscess
- C. Evacuates feces for a clean GI tract
- D. Evaluates the lymph system

Answer: B

Explanation:

Most abdomen CT scans require oral contrast (either barium sulfate or a water-soluble agent). Oral contrast helps visualize the intestinal lumen and it distends the intestinal tract. However, its use is so important because it helps the radiologist differentiate normal fluid-filled loops of bowel from an abnormal mass or abscess.

Question: 8

What window width and level setting adequately displays most soft tissue abdominal anatomy?

- A. 2,000/600
- B. 1,500/-600
- C. 450/50
- D. 150/70

Answer: C

Explanation:

This is the best window setting to view soft tissue abdominal anatomy for most patients.

Question: 9

What liver pathology is displayed as a well-defined, hypo-dense mass on an unenhanced image, and after contrast enhancement progressively enhances along the periphery and eventually is uniformly enhanced?

- A. Fatty infiltration
- B. Hemangioma
- C. Tumorous mass

D. Liver cyst

Answer: B

Explanation:

A hemangioma is a benign tumor that is often discovered incidentally during other imaging exams like ultrasound. Unenhanced hemangiomas appear as a well-defined hypo dense mass. After the lesion is enhanced, it begins a progressive pooling of contrast beginning at the periphery. Often, delayed images are done to confirm the lesions being uniformly enhanced after 10-15 minutes past injection.

Question: 10

CT is the imaging modality of choice for what abdominal organ?

- A. Pancreas
- B. Gallbladder
- C. Large intestines
- D. Stomach

Answer: A

Explanation:

CT is the imaging modality of choice for the best visualization of the pancreas. It provides more reliable overall diagnostic information than other imaging modalities. IV contrast helps provide a more detailed image of the pancreas. Water or other low-attenuation oral preps help to distinguish the duodenum from the pancreas without obscuring small stones.

Thank You for Trying Our Product

Special 16 USD Discount Coupon: NSZUBG3X

Email: support@examsempire.com

**Check our Customer Testimonials and ratings
available on every product page.**

Visit our website.

<https://examsempire.com/>